

Rowan University

Rowan Digital Works

Cooper Medical School of Rowan University
Capstone Projects

Cooper Medical School of Rowan University

2021

ORIF of Radius and Ulna Video Demonstration

Deep Patel

Cooper Medical School of Rowan University

David A. Fuller MD

Follow this and additional works at: https://rdw.rowan.edu/cmsru_capstones

Recommended Citation

Patel, Deep and Fuller, David A. MD, "ORIF of Radius and Ulna Video Demonstration" (2021). *Cooper Medical School of Rowan University Capstone Projects*. 52.

https://rdw.rowan.edu/cmsru_capstones/52

This Poster is brought to you for free and open access by the Cooper Medical School of Rowan University at Rowan Digital Works. It has been accepted for inclusion in Cooper Medical School of Rowan University Capstone Projects by an authorized administrator of Rowan Digital Works.

ORIF of Radius and Ulna Video Demonstration



Cooper Medical School
of Rowan University

1. Department of Orthopaedic Surgery, Cooper University Hospital 2. Cooper Medical School of Rowan University

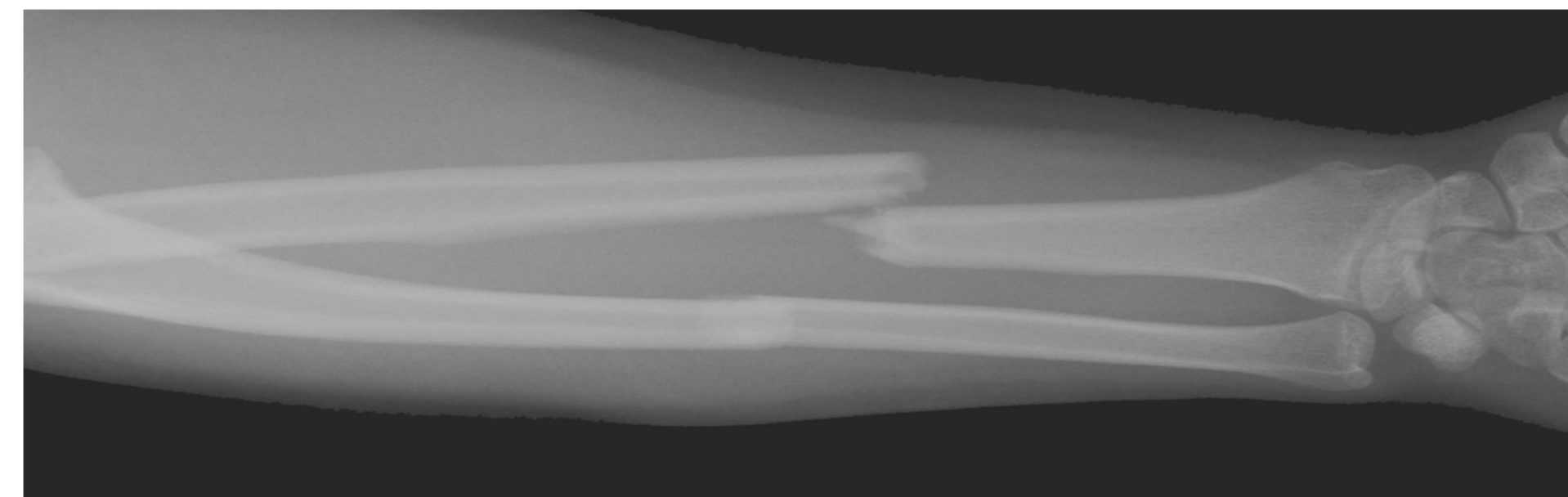
Deep K. Patel BS², David A. Fuller MD¹

Background

Video is an emerging medium that has become an invaluable resource within education. It allows for a multisensory, both visual and auditory, means for students to learn quickly and effectively. We hope to contribute to a growing peer-reviewed video library using this technology.

Case History

- 24-year-old, female involved in motor vehicle accident pain and deformity in non-dominant forearm



Research Question

Can we film and produce high-quality educational video content for learners within the orthopaedic community?

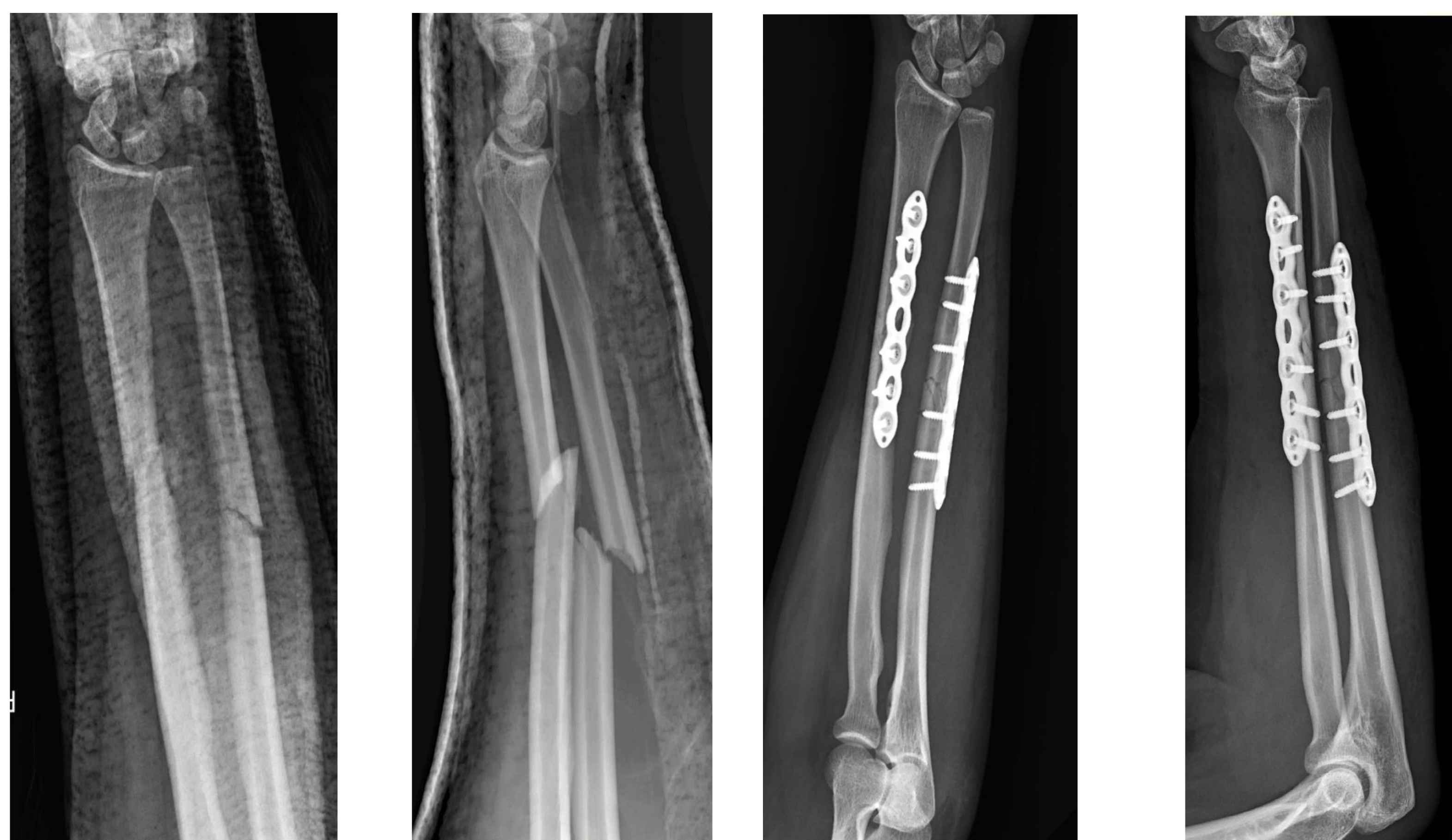

Fig 1: Pre-operative closed reduction X-Ray films

Fig 2: Post-operative ORIF X-Ray films

These are films taken of the patient at Cooper University Hospital prior to and after surgical intervention

Methods and Materials

Indication for Surgery:

- Displaced, unstable forearm shaft fractures

Positioning:

- Supine

2 Approaches were demonstrated:

- Direct, Subcutaneous - Ulna
- Anterior (Henry*) - Radius

Implants used:

- 3.5 dynamic, compression plates

Filming:

- A digital single-lens reflex camera, video editing software, USB condenser microphone

Results

- A video was directed, filmed and produced demonstrating surgical techniques used for definitive fixations of these fractures

Discussion

- During pre-operative planning, video angles and key shots of interest were established
- During filming it was critical to maintain the surgical sterile field and patient safety
- During production, the audience was critically considered - addressing video length and narration to maintain attention and interest

Future Directions:

- This video demonstration contributes to a growing library of peer-reviewed video educational content facilitating the advancement of medical education

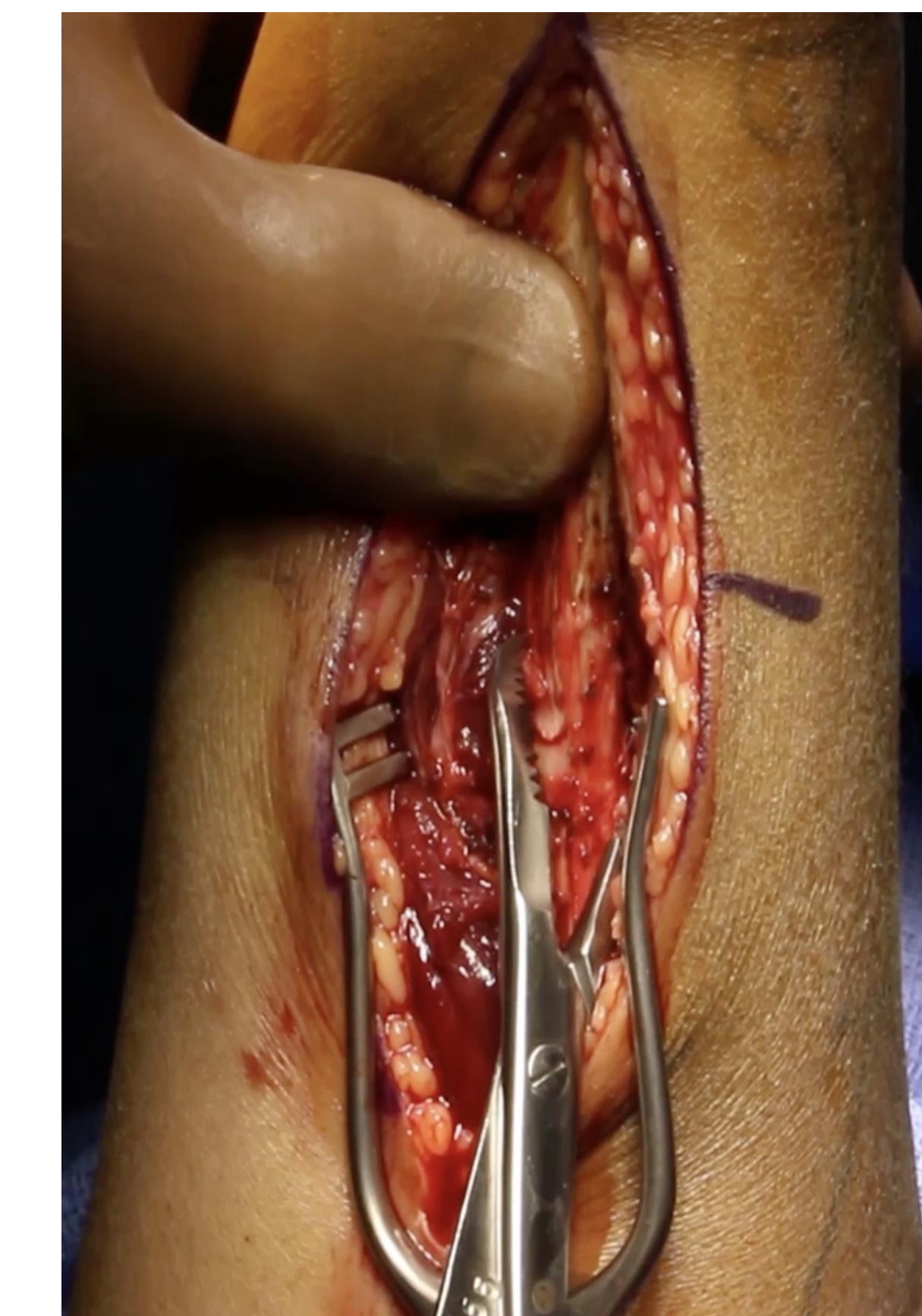

Fig 3: Anatomic reduction

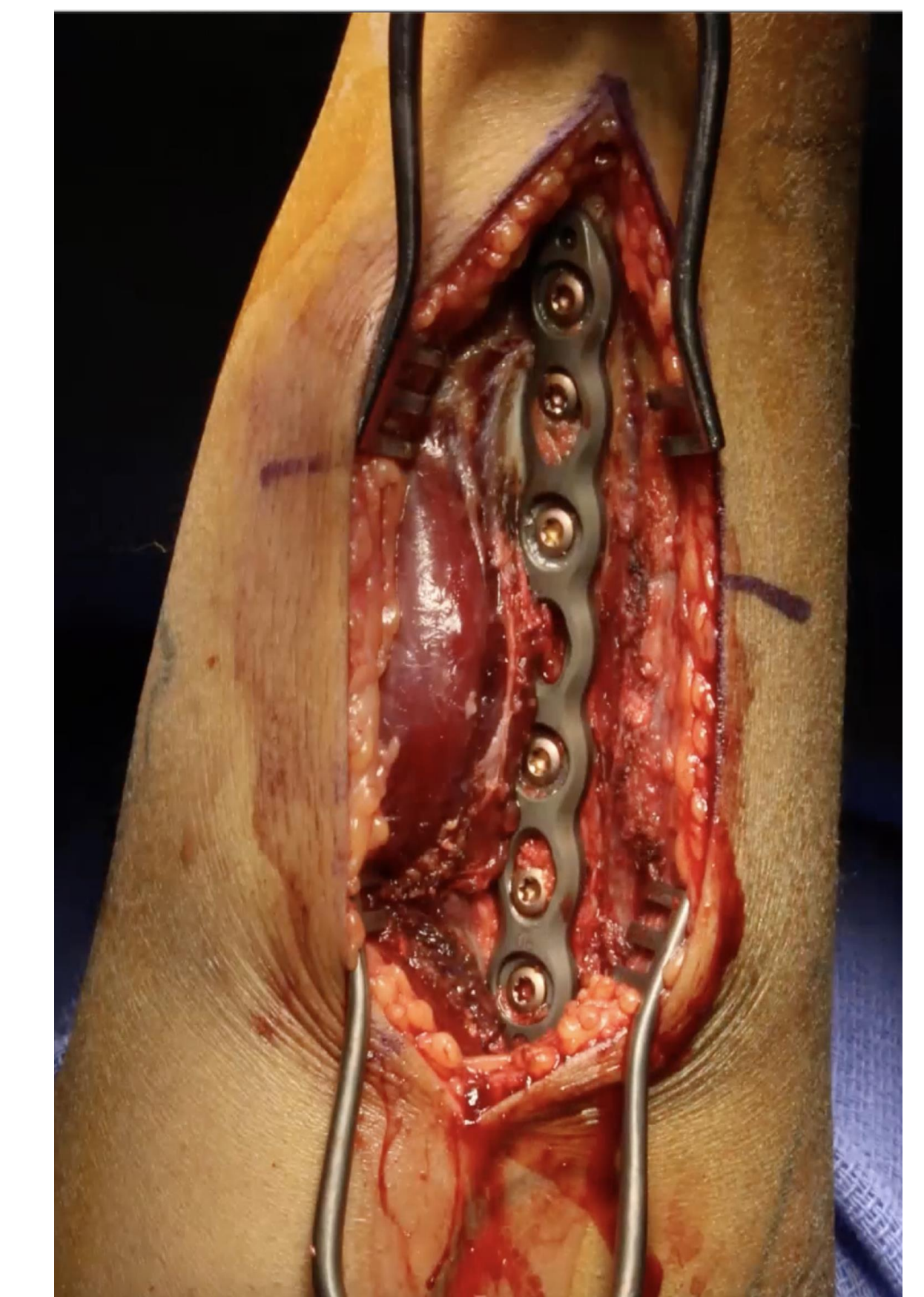

Fig 4: Plate fixation

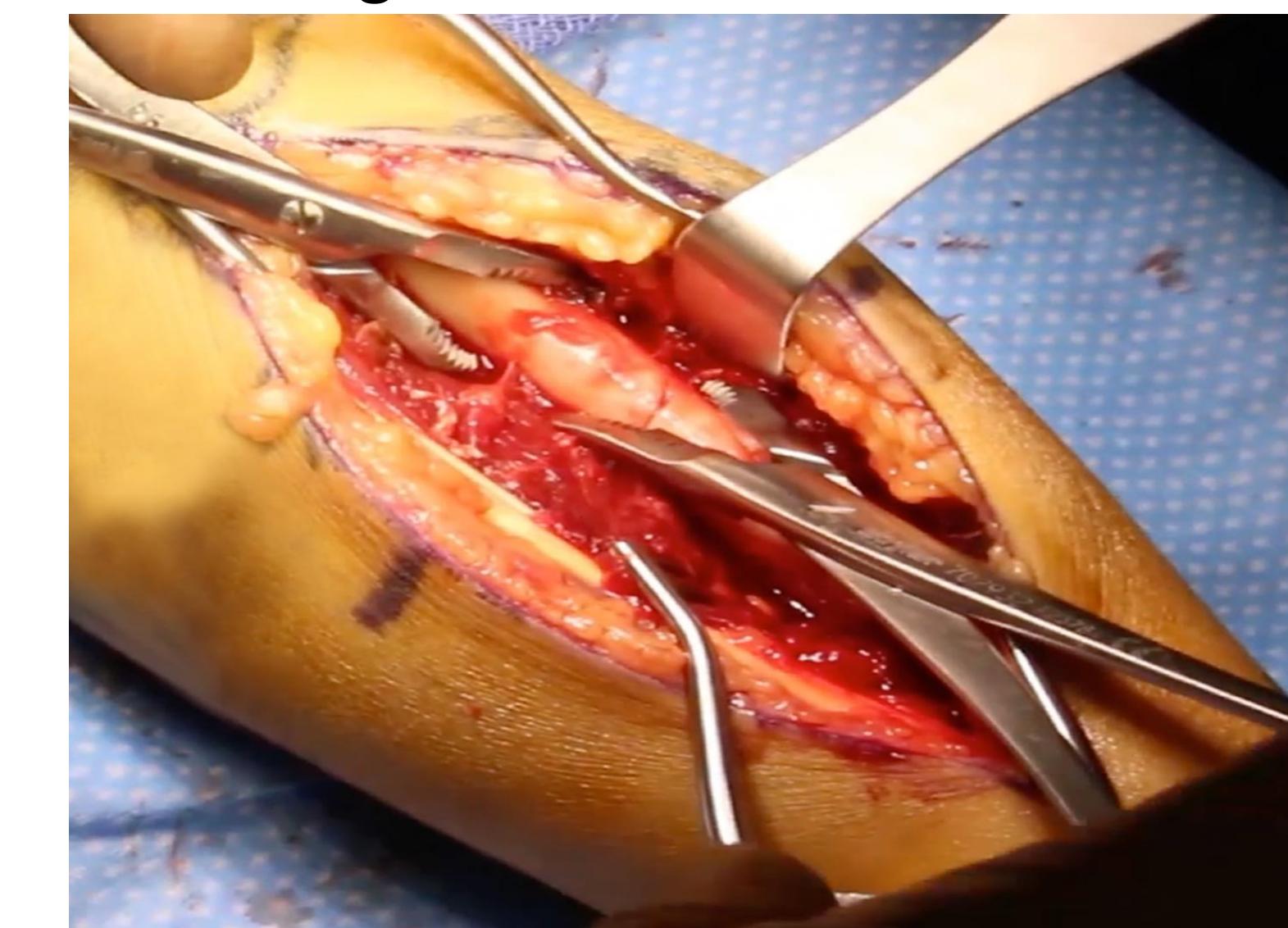

Fig 5: Anatomic reduction

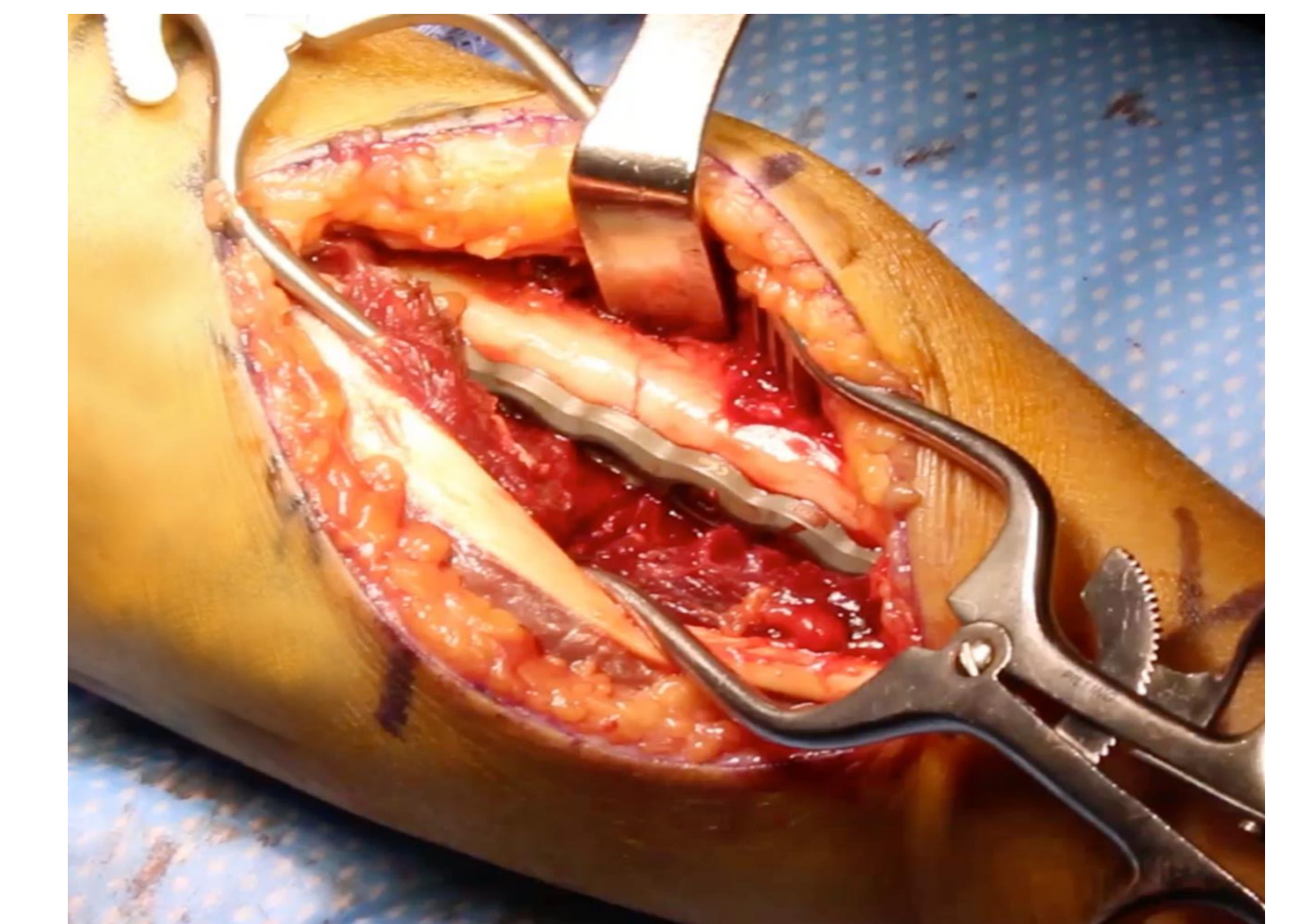


Fig 6: Plate fixation

These images display intra-operative reductions and definitive fixations of this patient's fractures

Acknowledgements

A special thank you to Dr. David Fuller for his continuous mentorship, guidance and support

References

- Ahmet, A., et al. (2018). "Is Video-Based Education an Effective Method in Surgical Education? A Systematic Review." *J Surg Educ* **75**(5): 1150-1158.
- Anderson, L. D., et al. (1975). "Compression-plate fixation in acute diaphyseal fractures of the radius and ulna." *J Bone Joint Surg Am* **57**(3): 287-297.
- Brame, C. J. (2016). "Effective Educational Videos: Principles and Guidelines for Maximizing Student Learning from Video Content." *CBE Life Sci Educ* **15**(4).
- Chapman, M. W., et al. (1989). "Compression-plate fixation of acute fractures of the diaphyses of the radius and ulna." *J Bone Joint Surg Am* **71**(2): 159-169.
- Dong, C. and P. S. Goh (2015). "Twelve tips for the effective use of videos in medical education." *Med Teach* **37**(2): 140-145.