

Rowan University

## Rowan Digital Works

---

Rowan-Virtua Research Day

25th Annual Research Day

---

May 6th, 12:00 AM

### The Application of Point-of-Care Ultrasound in ED Intubations and Airway Access: A Systematic Review

Frank Wheeler  
*Rowan University*

James Espinosa  
*Rowan University*

Alan Lucerna  
*Rowan University*

Jeffrey Gardecki  
*Rowan University*

Follow this and additional works at: [https://rdw.rowan.edu/stratford\\_research\\_day](https://rdw.rowan.edu/stratford_research_day)



Part of the [Analytical, Diagnostic and Therapeutic Techniques and Equipment Commons](#), [Cardiovascular Diseases Commons](#), [Emergency Medicine Commons](#), [Health and Medical Administration Commons](#), and the [Radiology Commons](#)

Let us know how access to this document benefits you - share your thoughts on our [feedback form](#).

---

Wheeler, Frank; Espinosa, James; Lucerna, Alan; and Gardecki, Jeffrey, "The Application of Point-of-Care Ultrasound in ED Intubations and Airway Access: A Systematic Review" (2021). *Rowan-Virtua Research Day*. 86.

[https://rdw.rowan.edu/stratford\\_research\\_day/2021/may6/86](https://rdw.rowan.edu/stratford_research_day/2021/may6/86)

This Poster is brought to you for free and open access by the Conferences, Events, and Symposia at Rowan Digital Works. It has been accepted for inclusion in Rowan-Virtua Research Day by an authorized administrator of Rowan Digital Works.

# The Application of Point-of-Care Ultrasound in ED Intubations and Airway Access: A Systematic Review

Frank Wheeler DO, James Espinosa MD, Alan Lucerna DO, Jeffrey Gardecki DO

**Emergency Medicine Residency and Department of Emergency Medicine, Jefferson SOM**

## Abstract:

Intubation is an essential procedure performed on a routine basis in the emergency room. Unsuccessful intubations are associated with deleterious outcomes. A systematic review was performed to investigate the accuracy of point of care ultrasound (POCUS) in successful Endotracheal Tube (ET) tube confirmation, utilizing ultrasonography, identification of the cricothyroid membrane utilizing ultrasound, and dynamically during use of ultrasonography in the process of intubation. This review demonstrated high sensitivity and specificity for ultrasound confirmation of ET tube placement, high success rate in ultrasound-guided intubation, and lower than expected accuracy in identifying the cricothyroid membrane. Ultrasonography should be considered for ET tube confirmation in patients in cardiac arrest and future applications of ultrasound may include dynamically during the process of intubation, intubation in real-time.

## Introduction:

Securing an airway is a critical procedure completed routinely in the Emergency Department (ED). Failing to obtain an airway carries severely adverse consequences which can result in significant morbidity and death. Traditional methods of confirming endotracheal tube placement include auscultation for bilateral breath sounds as well as ascertaining for tube condensation. However, these findings have been found to be unreliable.<sup>1</sup> Many consider end-tidal waveform capnography to be the gold standard to confirm ET tube placement, however in a patient in cardiac arrest, the sensitivity of this method decreases significantly.<sup>2</sup> A procedure that is not routinely performed but can be critical to establishing an airway is cricothyroidotomy. Success of a cricothyroidotomy is dependent on accurate identification of the cricothyroid membrane. Identifying the cricothyroid membrane by inspection and palpation is significantly low, especially in patients that are obese.<sup>3,4</sup> In the review, we will discuss the accuracy of ET tube confirmation utilizing ultrasonography, identification of the cricothyroid membrane utilizing ultrasound, and use of ultrasonography in the process of intubation.

## Materials and Methods:

This review is structured in accordance with the Preferred Reporting Items for Systematic Reviews and Meta-analyses guidelines for systematic reviews (P.R.I.S.M.A.) guidelines.<sup>5</sup> A search was conducted of PubMed from inception to March 8, 2021. Bibliographies of selected studies were reviewed to ascertain for further relevant articles of interest. Inclusion criteria consisted of all case-studies, prospective trials, randomized controlled trials, and meta-analysis assessing ultrasound applications during intubation, confirmation of tube placement following intubation as well as identification of cricothyroid membrane. All included studies must have provided data regarding success or failure of ultrasound applications discussed above. Any not pertinent to the subject matter were excluded as well as duplicates.

## Results:

A total of 193 studies were found. PubMed yielded 162 studies with other sources providing an additional 31 studies. After removal of duplicates, 157 studies were screened. Twenty studies were selected. Five studies were case reports. Three studies were meta-analysis. Ten studies were randomized controlled trials and two were review articles. This systematic review included 3,483 participants. Two thousand nine hundred eighty-eight participants involved confirmation of endotracheal tube following intubation, 246 participants were involved in identification of the cricothyroid membrane, and 269 participants were involved in ultrasound application in real-time intubation. The overall sensitivity to confirm ET tube placement utilizing ultrasonography was 96.4% (95% CI 96.3975 ± 3.544). Specificity was 98.0% (95% CI 98.025 ± 1.364). Limitations were techniques utilized to confirm tube placement as well as sonographer training prior to studies. Accuracy of identification of cricothyroid membrane was 85.5% (95% CI 85.5 ± 8.82). Limitations was the variability in defining "accuracy", ultrasound method utilized, and study populations. Study subjects who are morbidly obese will cause significant differences between accuracy of ultrasound and external palpation.<sup>6</sup> The overall success rate of ultrasound-guided intubation was 98% (95% CI 98 ± 1.96). Limitations was the variability in the study populations, methods of utilizing ultrasound throughout the intubation, limited sample size, and contexts in which studies were performed.

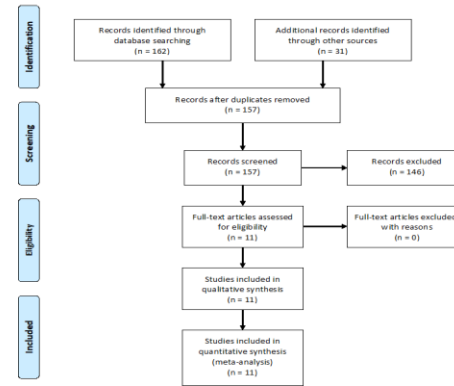


Figure 1: Preferred Reporting Items for Systematic Reviews and Meta-analysis Diagram

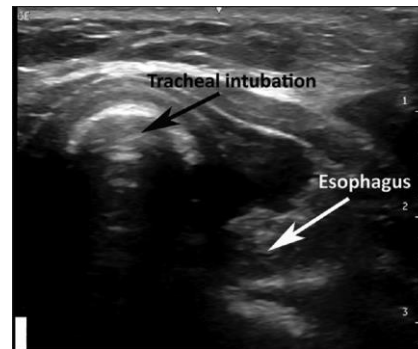


Figure 2: Confirming Tracheal Intubation

## Discussion:

This systematic review demonstrates that ultrasonography is very accurate in confirming intubation.<sup>7</sup> This correlates with previous studies demonstrating high efficacy in this respect.<sup>7</sup> Given capnography has been shown to be inaccurate in patients in cardiac arrest or massive pulmonary embolism and tube condensation has been shown to be a poor predictor of correct tube placement, ultrasound can be a useful modality to confirm endotracheal tube placement.<sup>1,8</sup>

The traditional method of ascertaining bronchial placement of endotracheal tube has been auscultation of bilateral lung sounds. However, recent studies have demonstrated auscultation of bilateral breath sounds is not specific for correct tube placement.<sup>9</sup> Ultrasound may also be a useful means to help demonstrate ventilation of both lungs. If ET tube is in correct position, bilateral equal motion of the diaphragm toward abdomen can be observed as well as bilateral lung sliding sign at the chest wall surface. If endobronchial placement is present, absence or restricted movement of the diaphragm as well as absence of lung sliding sign would be present on the non-ventilated side.<sup>10</sup>

Ultrasound may also be used to perform intubation in real-time and a high rate of success with this method has been demonstrated. Marciniak et al. demonstrated characteristic real-time ultrasound findings throughout intubation.<sup>11</sup> These included identification of trachea and tracheal rings, visualization of vocal cords, widening of glottis as tracheal tube passes through, tracheal tube positioning above carina and chest wall movement upon ventilation. Esophageal intubation can be readily recognized by visualizing tube in the paratracheal space. Other studies have demonstrated ultrasound-guided tracheal intubation with a styleted tracheal tubes.<sup>12,13</sup>

The accuracy of identifying the cricothyroid membrane was lower than expected. This may be secondary to the studies of interest were completing in those with difficult airways and morbid obesity. It can therefore postulate that this accuracy would be higher in those individuals with normal airways. The definition of accuracy was also very stringent in these studies, some only allowing success if identified with 5mm of actual cricothyroid membrane. The actual clinical significance of performing an incision greater than 5mm from actual cricothyroid membrane on the cricothyroidotomy success rate is unknown.

Overall, this systematic review provides evidence demonstrated high sensitivity and specificity for ultrasound confirmation of ET tube placement, high success rate in ultrasound-guided intubation, and lower than expected accuracy in identifying the cricothyroid membrane. Ultrasonography should be considered for tube confirmation in patients in cardiac arrest and future applications of ultrasound may include intubation in real-time.

## References:

1. Kelly JJ, Eynon CA, Kaplan JL, de Garavilla L, Dalseg WC: Use of tube condensation as an indicator of endotracheal tube placement. *Ann Emerg Med* May 1998;31:575-578.
2. MacLeod SA, Heller MB, Gerard JJ, et al. Verification of endotracheal tube placement with colorimetric end-tidal CO2 detection. *Ann Emerg Med*. 1991; 20: 267-270
3. Aslani A, Ng S-C, Hurley M, McCarthy KF, McNicholas M, McCaul CL. Accuracy of identification of the cricothyroid membrane in female subjects using palpation: an observational study. *Anesthesia and Analgesia* 2012; 114: 987-92.
4. You-Ten KE, Desai D, Postonogova T, Siddiqui N. Accuracy of conventional digital palpation and ultrasound of the cricothyroid membrane in obese women in labour. *Anaesthesia* 2015; 70: 2220-4.
5. Moher D, Liberati A, Tetzlaff J. Preferred Reporting Items for Systematic Reviews and Meta-analyses: the PRISMA Statement. *Ann Intern Med*. 2009; 151: 264-269
6. Siddiqui N, Yu E, Boulis S, You-Ten KE. Ultrasound is Superior to Palpation in Identifying the Cricothyroid Membrane in Subjects with Poorly Defined Neck Landmarks: A Randomized Clinical Trial. *Anesthesiology*. 2018 Dec;129(6):1132-1139. doi: 10.1097/ALN.0000000000002454. PMID: 30260895.
7. Tejesh CA, Manjunath AG, Shivakumar S, Vinayak PS, Yash B, Geetha CR. Sonographic detection of tracheal or esophageal intubation: A cadaver study. *Saudi J Anaesth*. 2016 Jul-Sep;10(3):314-6. doi: 10.4103/1658-354X.174922. PMID: 27375387; PMCID: PMC4916816.
8. Cook TM, Nolan JP. Use of capnography to confirm correct tracheal intubation during cardiac arrest. *Anaesthesia* 2011; 66: 1183-4.
9. Grmec S. Comparison of three different methods to confirm tracheal tube placement in emergency intubation. *Intensive Care Med*. 2002 Jun;27(6):701-4. doi: 10.1007/s00134-002-1290-x. Epub 2002 Apr 30. PMID: 12107674.
10. Hsieh, Kai-Sheng; Lee, Cheng-Liang; Lin, Chu-Chung; Huang, Ta-Cheng; Weng, Ken-Pen; Lu, Wen-Hsien Secondary confirmation of endotracheal tube position by ultrasound image. *Critical Care Medicine*: September 2004 - Volume 32 - Issue 9 - p 5374-5377 doi: 10.1097/01.CCM.0000134354.20449.92
11. Marciniak, Bruno MD\*, Fayoux, Pierre MD†; Hébrard, Anne MD\*; Krivosic-Horber, Renée MD\*; Engelhardt, Thomas MD, PhD; Bissonnette, Bruno SC, MD, FRCP[C] Airway Management in Children: Ultrasonography Assessment of Tracheal Intubation in Real Time?, *Anesthesia & Analgesia*: February 2009 - Volume 108 - Issue 2 - p 461-465 doi: 10.1213/ane.0b013e31819240f5
12. Kundra, P., Padala, S.R.A.N. & Jha, A.K. Ultrasound guided tracheal intubation with a styleted tracheal tube in anticipated difficult airway. *J Clin Monit Comput* (2020)
13. John E, Fladpole, Paul Stricker, Harshad Gurnaney, Akira Nishiaki, Anna Rabinowitz, Avraham Gurwitz, John J. McCloskey, Arjunan Ganesh; Ultrasound-guided Tracheal Intubation: A Novel Intubation Technique. *Anesthesiology* 2012; 117:1389-1391