

Rowan University

## Rowan Digital Works

---

Rowan-Virtua Research Day

26th Annual Research Day

---

May 5th, 12:00 AM

### Bilateral Teratomas in Pediatric Patient with Unilateral Ovarian Torsion

David Ho  
*Rowan University*

Maya Borowczak  
*Rowan University*

Archana Verma  
*Children's Hospital of Philadelphia, Philadelphia, PA*

Follow this and additional works at: [https://rdw.rowan.edu/stratford\\_research\\_day](https://rdw.rowan.edu/stratford_research_day)



Part of the [Female Urogenital Diseases and Pregnancy Complications Commons](#), [Neoplasms Commons](#), [Obstetrics and Gynecology Commons](#), [Pathological Conditions, Signs and Symptoms Commons](#), and the [Pediatrics Commons](#)

Let us know how access to this document benefits you - share your thoughts on our [feedback form](#).

---

Ho, David; Borowczak, Maya; and Verma, Archana, "Bilateral Teratomas in Pediatric Patient with Unilateral Ovarian Torsion" (2022). *Rowan-Virtua Research Day*. 23.  
[https://rdw.rowan.edu/stratford\\_research\\_day/2022/May5/23](https://rdw.rowan.edu/stratford_research_day/2022/May5/23)

This Poster is brought to you for free and open access by the Conferences, Events, and Symposia at Rowan Digital Works. It has been accepted for inclusion in Rowan-Virtua Research Day by an authorized administrator of Rowan Digital Works.

# Bilateral Teratomas in Pediatric Patient with Unilateral Ovarian Torsion

By: David Ho DO<sup>1</sup>, Maya Borowicz MS-3<sup>2</sup>, Archana Verma MD<sup>3</sup>

<sup>1</sup>Jefferson Health New Jersey Department of Emergency Medicine

<sup>2</sup>Rowan University School of Osteopathic Medicine MS-3

<sup>3</sup>Children's Hospital of Philadelphia Department of Emergency Medicine

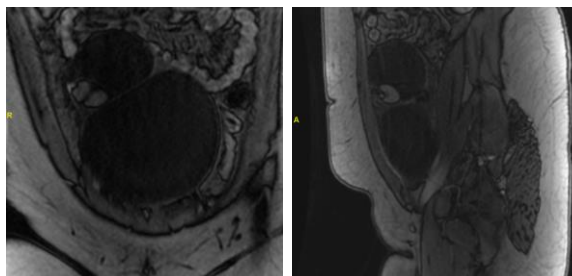
## ABSTRACT

Ovarian torsion is a surgical emergency found in both pediatric and adult populations. It involves the full or partial rotation of the vessels that supply the ovary, resulting in ischemia. In this report, we present the case of a pediatric patient arriving to the Pediatric Emergency Department (PED) for evaluation of right lower quadrant (RLQ) abdominal pain, who was found to have an ovarian torsion. In this particular case, the patient's ovarian torsion was due to a teratoma, and imaging would later identify an additional smaller teratoma on the contralateral side. **This case shows the importance of considering ovarian pathologies in abdominal tenderness of pediatric females.**

## CASE PRESENTATION

A 13-year-old female presented to the PED for RLQ pain that started 5 days ago and was described as sharp and constant. There were no associated urinary complaints. Menstruation occurred regularly. She had two episodes of NBNB emesis 3 days ago secondary to pain and diarrhea which had both since resolved. She was still with decreased PO intake. Patient denied trauma or injuries. Differential diagnosis includes UTI, pyelonephritis, nephrolithiasis, appendicitis, and ovarian pathology including torsion and ruptured cyst. Urinalysis was negative for signs of stone or infection. RLQ and pelvic (transabdominal) ultrasounds were ordered. Findings included a large complex cystic mass associated with the right ovary which obscured the doppler's ability to assess for torsion. Appendix was normal. A follow-up MRI was performed to investigate the complex cyst. On the right ovary, the **complex cyst was measured at 15.9 x 8.4 x 12.8 cm** with solid components and fat found in all sequences. Additionally, on the left ovary, there was another **complex cyst measured at 6.6 x 4.1 x 6.8 cm** again with solid components and fat found in all sequences.

On MRI, the right ovary demonstrated a tortuous appearance of the vasculature, concerning for **ovarian torsion**. The patient was evaluated by OB-GYN and taken to the OR for a laparotomy. Bilateral ovarian cysts were resected and then drained. The **right ovary was enlarged at 17 cm was found to be torsed 1.5 times**. The right fallopian tube was edematous and round ligament strained due to torsion. Three individual cysts were resected from the right ovary, and overall, **900 mL of cystic fluid was drained**. The surgeons noted that the left ovary appeared large at 7 cm, but without signs of torsion. Three cysts were also resected from the left ovary without rupture. Specimens were sent to pathology.



Left – MRI coronal view of the right teratoma  
Right – MRI sagittal view of the right teratoma

The pathology report for the **left ovary** showed a **smooth capsular surface containing a clear runny fluid, tan-white material mixed with hair, adipose tissue, calcifications, and skin consistent with a teratoma**. The **right ovary** pathology report contains **similar glistening capsule filled with tan-white fluid intermixed with hair, adipose tissue, calcifications, and skin also consistent with a teratoma**. The patient tolerated the procedure without difficulty and recovered in PACU.

## DISCUSSION

In this report, we discuss the case of a female pediatric patient presenting with RLQ pain, found to have bilateral ovarian teratomas causing an ovarian torsion on the right side. This case is unique in that ovarian torsions are rare in general, accounting for only 2.7% of abdominal pain cases<sup>4</sup>; the patient was outside the typical age range for torsion (20-40 years of age<sup>6</sup>); and she had bilateral teratomas (found in only 10% of teratoma cases<sup>1</sup>). Despite the rarity of the finding, this patient did exhibit the common presentation of ovarian torsion including RLQ pain along with nausea and vomiting<sup>5</sup>. This patient was unusual in that her torsion could not be accurately diagnosed with US and required follow-up MRI and ultimately laparoscopy to confirm it. In cases in which ovarian torsions are suspected but imaging is negative, the gold standard investigative modality is the diagnostic laparoscopy. **The significance in a case such that this is to always consider ovarian pathology in female pediatric patients with RLQ pain.**

## REFERENCES

1. Outwater, Eric K., et al. "Ovarian Teratomas: Tumor Types and Imaging Characteristics." *RadioGraphics*, vol. 21, no. 2, 2001, pp. 475–490., <https://doi.org/10.1148/radiographics.21.2.g01mr09475>.
2. Saleh, Mohammed, et al. "Ovarian Teratomas: Clinical Features, Imaging Findings and Management." *Abdominal Radiology*, vol. 46, no. 6, 2021, pp. 2293–2307., <https://doi.org/10.1007/s00261-020-02873-0>.
3. Kwon, Hye Jin. "Torsion of Ovarian Teratoma in a Child before Menarche." *Journal of Pediatric Surgery Case Reports*, vol. 77, 2022, p. 102170., <https://doi.org/10.1016/j.epsc.2021.102170>.
4. Childress, Krista J., and Jennifer E. Dietrich. "Pediatric Ovarian Torsion." *Surgical Clinics of North America*, vol. 97, no. 1, 2017, pp. 209–221., <https://doi.org/10.1016/j.suc.2016.08.008>.
5. Walls, Ron M., et al. *Rosen's Emergency Medicine: Concepts and Clinical Practice*. Elsevier, 2018.
6. Dasgupta, Roshni, et al. "Ovarian Torsion in Pediatric and Adolescent Patients: A Systematic Review." *Journal of Pediatric Surgery*, vol. 53, 20 Oct. 2017, pp. 1387–1391., <https://doi.org/https://doi.org/10.1016/j.jpedsurg.2017.10.053>.