

Rowan University

Rowan Digital Works

Rowan-Virtua Research Day

26th Annual Research Day

May 5th, 12:00 AM

Case Study of Metformin-Induced Lactic Acidosis

Kajel Patel

Rowan University

Kishan Patel

Rowan University

Follow this and additional works at: https://rdw.rowan.edu/stratford_research_day



Part of the [Endocrine System Diseases Commons](#), [Endocrinology, Diabetes, and Metabolism Commons](#), [Nephrology Commons](#), [Nutritional and Metabolic Diseases Commons](#), [Pathological Conditions, Signs and Symptoms Commons](#), [Pharmaceutical Preparations Commons](#), and the [Urology Commons](#)

Let us know how access to this document benefits you - share your thoughts on our [feedback form](#).

Patel, Kajel and Patel, Kishan, "Case Study of Metformin-Induced Lactic Acidosis" (2022). *Rowan-Virtua Research Day*. 40.

https://rdw.rowan.edu/stratford_research_day/2022/May5/40

This Poster is brought to you for free and open access by the Conferences, Events, and Symposia at Rowan Digital Works. It has been accepted for inclusion in Rowan-Virtua Research Day by an authorized administrator of Rowan Digital Works.

Abstract

Metformin induced lactic acidosis is when high levels of metformin cause dangerously high levels of lactic acid. Here is a case report of a 72 year-old female who came in for nausea, vomiting, and diarrhea found to have a high suspicion for metformin induced lactic acidosis. She stabilized in the emergency department, nephrology and ICU was contacted, and she went for emergent dialysis. For many patients the prognosis of metformin induced lactic acidosis is poor. This patient was made comfort care by her family.

Introduction

These are the definitions of metformin induced lactic acidosis (MILA) vs metformin-associated lactic acidosis (MALA) vs metformin-unrelated lactic acidosis (MULA). MILA is high levels of metformin in the system is the primary cause of the patient illness and can occur both acutely with metformin overdose or subacute accumulation of metformin due to renal failure. MALA is when patients are on metformin and develop an acute life-threatening illness such as septic shock, in which metformin intensifies the degree of lactic acidosis, but is not the sole cause of the patient's illness. MULA is when the patient is on metformin and levels are low unrelated to patient's illness. The spectrum of all of these disease process are difficult to differentiate from one another. The reason there is an increase in lactic acid is because it inhibits the mitochondrial transport chain, which causes NADH to accumulate and substrates in kreb cycle to get backed up which causes pyruvate to get converted into lactate instead of going into the Kreb cycle like it is supposed to. Figure 1. The clinical signs of metformin toxicity can be seen with GI symptoms, which are nausea, vomiting, diarrhea and epigastric pain. Patient can also have altered mental status, hypothermia, and hypotension that is not responsive to vasopressors. This disease process is rare, and difficult to diagnose at time, and usually the prognosis is poor. The worse the acidemia the worse the prognosis becomes.

Discussion

This patient is one who is difficult to differentiate if it were metformin-induced lactic acidosis vs metformin-associated lactic acidosis. This patient had been taking metformin at home and since she had dementia was unclear how much she was taking, which gives us a concern for MILA. Patient also had acute kidney injury from a normal kidney function on prior labs few months ago. It is difficult to ascertain if she was developing chronic kidney disease which caused her metformin levels to build up, or if she had a more acute kidney injury from reduced po intake that caused her metformin levels to go up. Patient's urinalysis did look infected which would suggest MALA, physiologic stressors was not evident on neutrophil to lymphocyte ratio which is used as surrogate for underlying sepsis. The UA is unreliable because it might be falsely positive due to dehydration which we can ascertain from the high specific gravity. Empiric antibiotics were started however there was still concern for metformin induced lactic acidosis. Whether the patient had MILA or MALA she would have needed dialysis to dialyze out the metformin in her system. Given sirs criteria, with lactic acidosis, with unreliable history from patient, empiric antibiotics were warranted.

Case Study of Metformin Induced Lactic Acidosis By Kajel Patel, DO ; Kishan Patel, DO

Figure 1

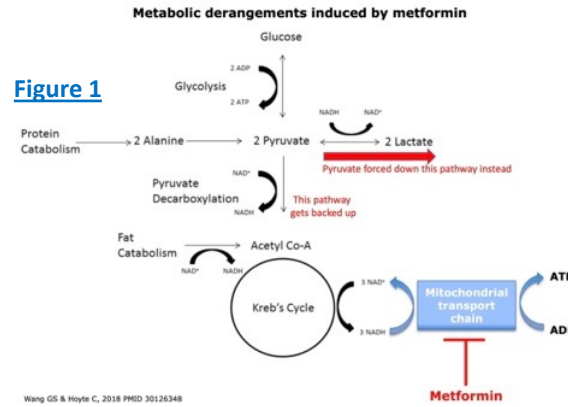



Figure 2



References:

- Blough, B., Moreland, A., & Mora, A. (2015, January). *Metformin-induced lactic acidosis with emphasis on the anion gap*. Proceedings (Baylor University. Medical Center). Retrieved March 28, 2022, from <https://www.ncbi.nlm.nih.gov/pmc/articles/PMC4264704/>
- Farkas, J. (2021, November 30). *Metformin toxicity*. EMCrit Project. Retrieved March 28, 2022, from <https://emcrit.org/ibcc/metformin/>

Conclusion

Metformin induced lactic acidosis is a rare but an important diagnosis to consider in patients with elevated lactate that are on metformin. Suspicion for MILA increases when patient has higher metformin dose, chronic or subacute renal failure with markedly reduced GFR (since metformin is renally excreted), no other obvious causes of elevated lactate, and no response to basic supportive/resuscitative measures as seen in Figure 2 Treatment includes respiratory support, fluid resuscitation, and ultimately dialysis to help filter out the circulating metformin. Prognosis for MILA is usually poor, especially in patients who come in profoundly acidotic. It is important to try to keep this in your differential and reach out to nephrology for emergent dialysis as soon as possible.

Case Report

72 y.o. female with history of hypertension, hyperlipidemia, diabetes, and dementia coming in for shortness of breath, nausea, vomiting, and diarrhea. Patient states that she has been having symptoms for 2 weeks. Abdominal pain was described as diffuse and intermittent in nature. She states shortness of breath began this morning. She denies chest pain, fevers or chills She has been vaccinated and boosted for COVID-19. She denies any history of DVT or PE. Denies any recent travel or cancer history. History was limited due to patient's dementia.

Past Medical Hx: Dementia, Cirrhosis of liver without ascites, DM, HTN, HLD, Osteoporosis
Meds: metformin 1000mg daily, ASA 81mg daily, Carvedilol 6.25 twice a day, Lasix 20mg daily, Memantine 5mg BID, vitamin C 1000mg table, Vitamin D3 1000units daily, losartan 50mg, Xifaxan 550mg BID,
Allergies: Forteo (teriparatide)
No pertinent past surgical or social History

Physical exam on first arrival: Unremarkable, abdomen soft nontender, heart rate regular rate and rhythm, , tachypnea, normal lung sounds, mild lower extremity edema bilaterally

Initial vital signs: Temperature 97.9°, heart rate 75, respiratory rate 20, blood pressure 95/42 map is 60, pulse ox 88% on RA

Labs: BMP: Sodium 131, potassium 5.4, chloride 102, bicarb 6, anion gap 23, BUN 46, creatinine 3.03, GFR 16, glucose 54, calcium 9.1, total protein 5.0, albumin 2.8, T bili 1.7, direct bili 0.6, alk phos 59, AST 43, ALT 27, lipase 104
CBC: WBC 9.6, RBCs 2.3, hemoglobin 7.6, hematocrit 25.4, MCV 108.6, platelets 152, neutrophil percentage 75.1, lymphocytes 13.0, monocytes 11.1, eosinophils 0.4, basophils 0.4; Lactate: 13.7, BNP 133; ABG: PH 7.16, pCO2 less than 19, PO2 176, oxygen saturation 99.9 on nasal cannula 2 L Urinalysis: Yellow, hazy, trace ketones, 3+ leukocytes, many bacteria, rare calcium oxalate, hyaline cast, 82 wbc's

CT chest, abd, pelvis: showed no acute chest abdomen or pelvis findings

Patient was intubated in the ED for worsening mental status and tachypnea. Nephrology was consulted who agreed with the concern for the metformin induced lactic acidosis and patient was given 150 meq NaHCO3, started on full strength bicarb drip and was scheduled for emergent dialysis. Patient was admitted to the ICU where emergent dialysis took place. On re-examination patient had become more Tachypnic and confused. Decision was made to intubate patient prior to getting dialysis. Patient was intubated and ICU was called. Patient also received a CT chest, abdomen and pelvis while dialysis was getting set up which was unremarkable.