

Rowan University

Rowan Digital Works

Rowan-Virtua Research Day

28th Annual Research Day

May 2nd, 12:00 AM

A Stroke or Not a Stroke? A Case of Chronic Hemiplegic Migraines

Bum J. Kim

Rowan University

Matthew Orap

Rowan University

Bret Farrow-Cypel

AtlantiCare Regional Medical Center

Naseer Ahmed

AtlantiCare Regional Medical Center

Follow this and additional works at: https://rdw.rowan.edu/stratford_research_day



Part of the [Diagnosis Commons](#), [Nervous System Diseases Commons](#), [Neurology Commons](#), and the [Pathological Conditions, Signs and Symptoms Commons](#)

Let us know how access to this document benefits you - share your thoughts on our [feedback form](#).

Kim, Bum J.; Orap, Matthew; Farrow-Cypel, Bret; and Ahmed, Naseer, "A Stroke or Not a Stroke? A Case of Chronic Hemiplegic Migraines" (2024). *Rowan-Virtua Research Day*. 11.

https://rdw.rowan.edu/stratford_research_day/2024/may2/11

This Poster is brought to you for free and open access by the Conferences, Events, and Symposia at Rowan Digital Works. It has been accepted for inclusion in Rowan-Virtua Research Day by an authorized administrator of Rowan Digital Works.

A Stroke or Not a Stroke? A Case of Chronic Hemiplegic Migraines

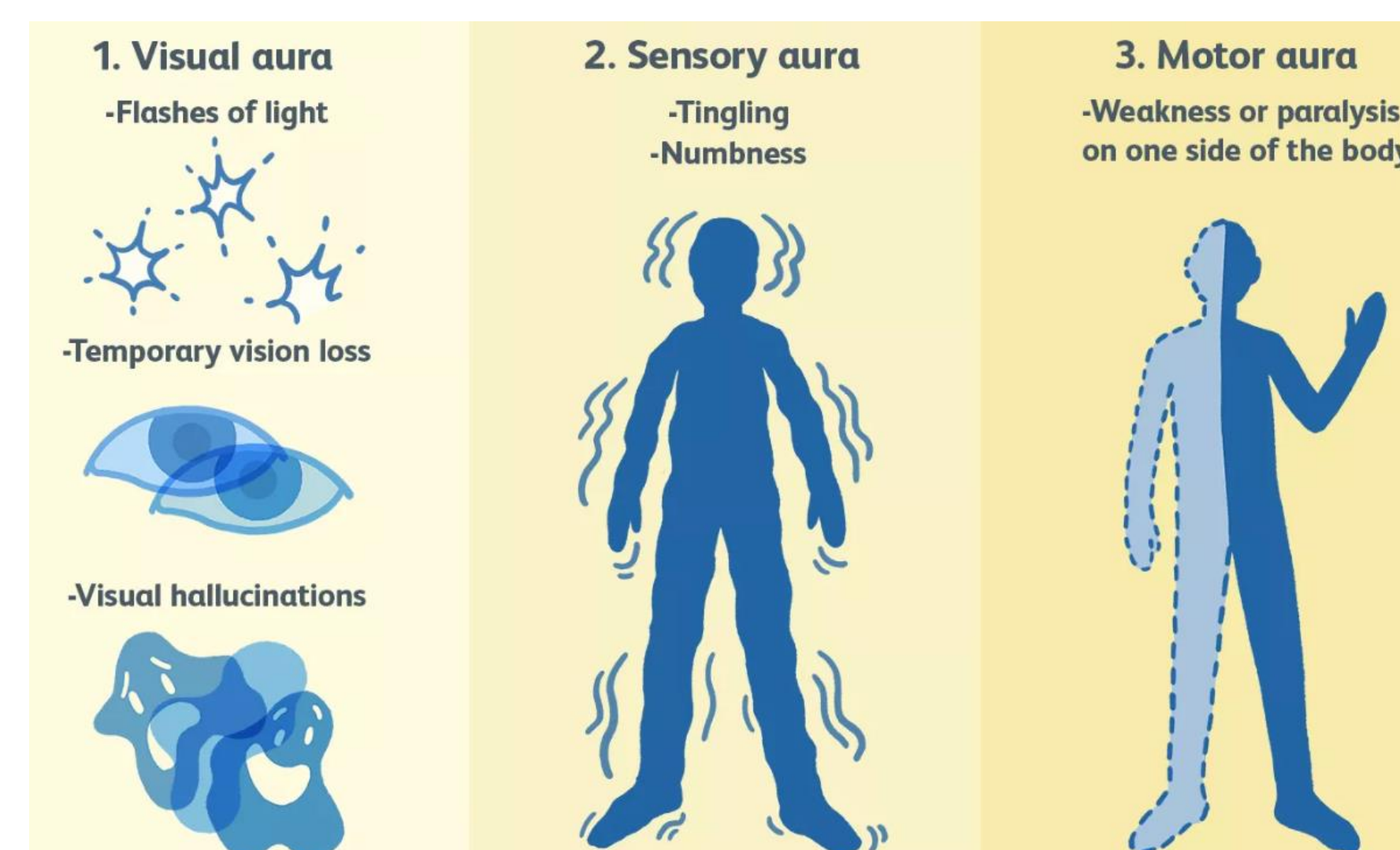
Bum Kim OMS, Matthew Orap OMS, Bret Farrow-Cypel DO, Naseer Ahmed MD
Internal Medicine of AtlantiCare Regional Medical Center, Atlantic City, N.J., U.S.A.

Introduction

Hemiplegic migraine (HM) is a rare subtype of migraine with both familial and sporadic patterns. These migraines present episodically with reversible attacks of unilateral motor weakness. Patients may experience visual changes, sensory loss, impaired level of consciousness, ataxia, and speech changes. Symptoms can last from hours to days and can mimic an acute stroke. This rare condition has a prevalence of .01% with females having higher prevalence than males with the ratio of 2.5:1. The genetic tie with the familial cause has been associated with mutations in CACNA1A, ATP1A2, and SCN1A genes which are transmitted in an autosomal dominant pattern.

Case

The patient is a 45-year-old male with a past medical history of hypertension, possible cerebral vascular accident, alcohol use disorder, tobacco use disorder, and cannabis use who presents to the emergency department complaining of left extremity numbness and weakness. The patient is afebrile with a blood pressure of 148/104 mm Hg. He shows loss of motor and sensory functions in the left extremities with slurred speech and left-sided facial droop. Initial labs were only notable for a Urine Drug Screen positive for cannabis. CT head showed no acute findings and CT angiogram showed no large vessel occlusion. Tenecteplase was administered and the patient was admitted to the neurologic intensive care unit due to high suspicion of stroke by neurology. High intensity statin was started and an MRI of the brain without contrast was ordered which showed no pertinent findings. NIH stroke score was 6 with diminished motor functions in the left arm loss of sensation to pin prick, moderate aphasia, and dysarthria.



<https://www.verywellhealth.com/hemiplegic-migraines-3862389>

Case continued

On the following day, another unremarkable CT head result downgraded the patient to telemetry. The patient reports a return to baseline without any neurologic deficits, ataxia, dysarthria, or paresthesia. The patient elaborates that similar episodes occur approximately 10 times a month that are usually milder in intensity. The episodes begin as a sharp headache just above the occiput on the left side and radiate down to his left hand before going down the left side of the legs. Preceding the episodes, he reports seeing "white speckles" and experiencing both phono and photosensitivity. Paresthesia is then experienced with diminished motor functions and dysarthria. The symptoms generally persist for about two hours and resolve spontaneously. He states that stress can increase the frequency and intensity of episodes with some alleviation of symptoms with the use of marijuana. The patient also mentioned that his first onset was 10 years ago within the year of a motor vehicle accident. A similar severity of symptoms led to his hospitalization 5 years ago with a stroke diagnosis. Recent imaging showed no evidence of prior cerebrovascular accident and the patient has no residual deficits.

Intervention

The patient was provided education on migraines. Atorvastatin, lisinopril, and propranolol were prescribed to control his hypertension that can decrease frequency of migraine and prevent ischemic strokes. Lifestyle management including sleep hygiene, stress reduction, hydration, and avoiding triggers was discussed. While the patient expressed his interest in leaving the hospital against medical advice, he was encouraged to return if the symptoms worsened.

References

- Charles, A., & Brennan, K. (2009). Cortical spreading depression—new insights and persistent questions. *Cephalalgia*, 29(10), 1115–1124. <https://doi.org/10.1111/j.1468-2982.2009.01983.x>
- Thomsen, L. H., & Olesen, J. (2004). Sporadic hemiplegic migraine. *Cephalalgia*, 24(12), 1016–1023. <https://doi.org/10.1111/j.1468-2982.2004.00788.x>
- Goadsby, P. J., Lipton, R. B., & Ferrari, M. D. (2002). Migraine — Current understanding and treatment. *The New England Journal of Medicine (Print)*, 346(4), 257–270. <https://doi.org/10.1056/nejmra010917>
- Danesh, A., & Gottschalk, P. (2019). Beta-Blockers for Migraine Prevention: a Review Article. *Current Treatment Options in Neurology*, 21(4). <https://doi.org/10.1007/s11940-019-0556-3>
- Ducros, A., Denier, C., Joutel, A., Cécillon, M., Lescoat, C., Vahedi, K., Darcel, F., Vicaut, É., Bousser, M., & Tournier-Lasserre, E. (2001). The Clinical Spectrum of Familial Hemiplegic Migraine Associated with Mutations in a Neuronal Calcium Channel. *The New England Journal of Medicine (Print)*, 345(1), 17–24. <https://doi.org/10.1056/nejm200107053450103>

Discussion

The diagnosis of hemiplegic migraine is clinical and genetic testing is not necessary for all patients. The patient's symptoms fulfilled the key diagnostic criteria of episodic, reversible motor weakness starting with migraine aura with at least one other aura (visual, sensory, aphasic). Starting with visual auras, the patient experienced motor weakness along with dysarthria, phonophobia, and photophobia. In addition, these symptoms were fully reversible leaving no residual deficits. The patient's more common differentials of cerebrovascular accident, cervical stenosis, infection, and electrolyte abnormalities were dismissed following multiple neuroimaging, infectious, and metabolic workups.

There are currently no randomized controlled trials of therapy for hemiplegic migraines, but a few case reports and small series of multiple medication treatments. A small study suggests verapamil to be helpful in frequent or prolonged aura. Unlike migraines, vasoconstrictors like triptans are avoided to decrease risk of ischemia in hemiplegic migraines. Our approach to treating this patient was starting with NSAIDs during the time of the episode and controlling hypertension. The patient was not on any medications and as beta blockers were shown to be effective in migraine prophylaxis and controlling hypertension, it was suggested and started for the patient.

Limitation/Conclusion

The patient had no other family in the area and was unsure of his familial history. The patient was rushing to get to work even signing out against medical advice suggesting noncompliance with treatment. It would be difficult to obtain follow up information. Genetic testing options are usually done outpatient and the patient is not interested in maintenance treatment when the symptoms are not present.

A 45 year old male patient with PMH of hypertension and possible CVA presented with left sided weakness. When the labs and imaging show up negative for a stroke and the patient has repeated similar episodes with headaches think hemiplegic migraines.